

medical education supplementary fund project

virtual microscopy for teaching histology

Anthony W.I. Lo

Anatomical and Cellular Pathology

22nd October, 2011

background

- histology
 - the study of cell morphology
 - bases of life and diseases
 - learn for basic medical sciences and pathology
- medical students
 - have their own microscopes
 - have their own sets of teaching slides

what is the problem?

- increased number of students
- difficult to manage many microscopes
- keeping many sets of slides is a headache

the plan is ...

- a digital library of teaching slides
 1. images of the entire slide, can zoom in and out
 2. find the areas of interest on your own
 3. through internet
 4. allow interactive teaching

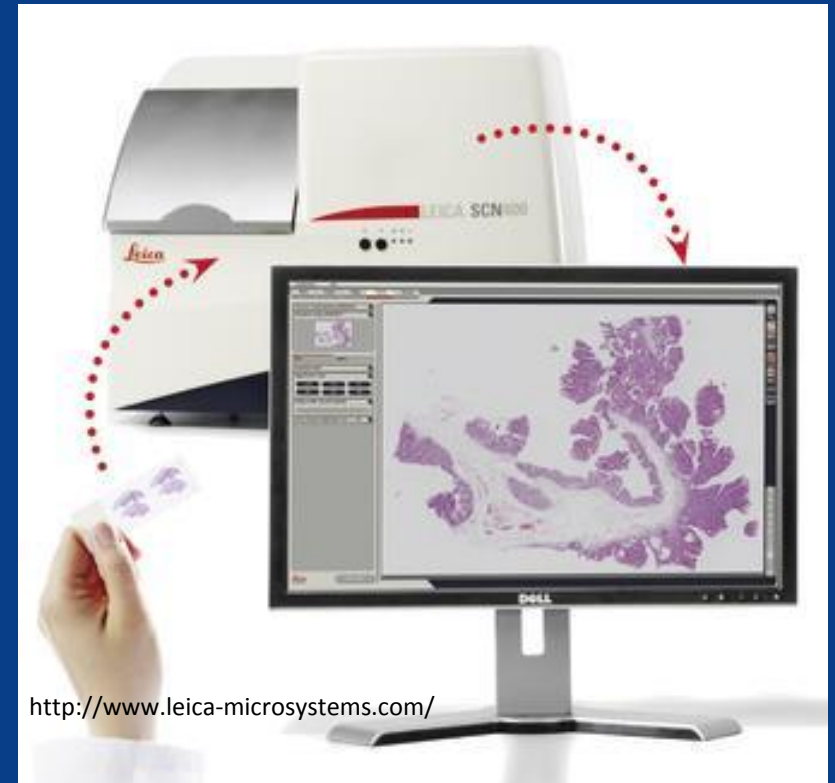we are working on ...

- get the digital whole slide scanner
 - CUHK bursary + our Faculty + SBS + ACP + mesf
- get the software
 - SlidePath, Digital Slidebox
- build the digital library of teaching slides
- other possibilities? your call.

in a few months' time, ...



current state at 5/F, Cancer Center
PWH (Oct 22, 2011)

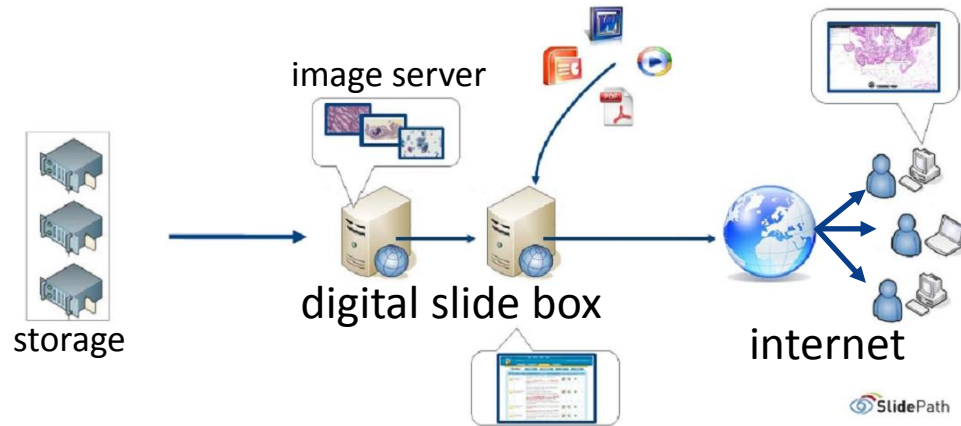
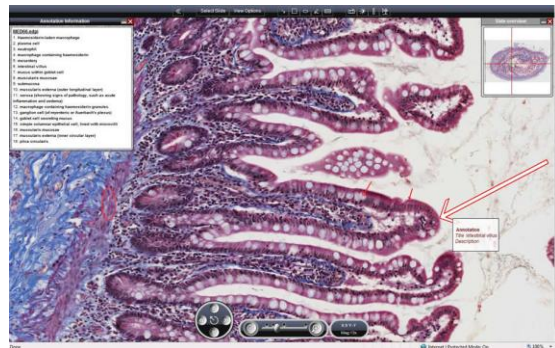


Leica SCN400 whole slide scanner

a little more time later ...

digital images

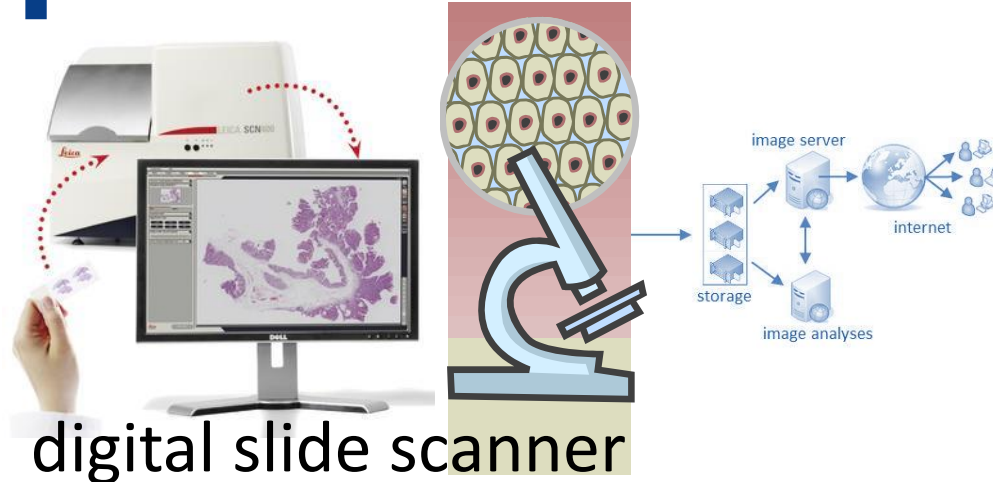
students



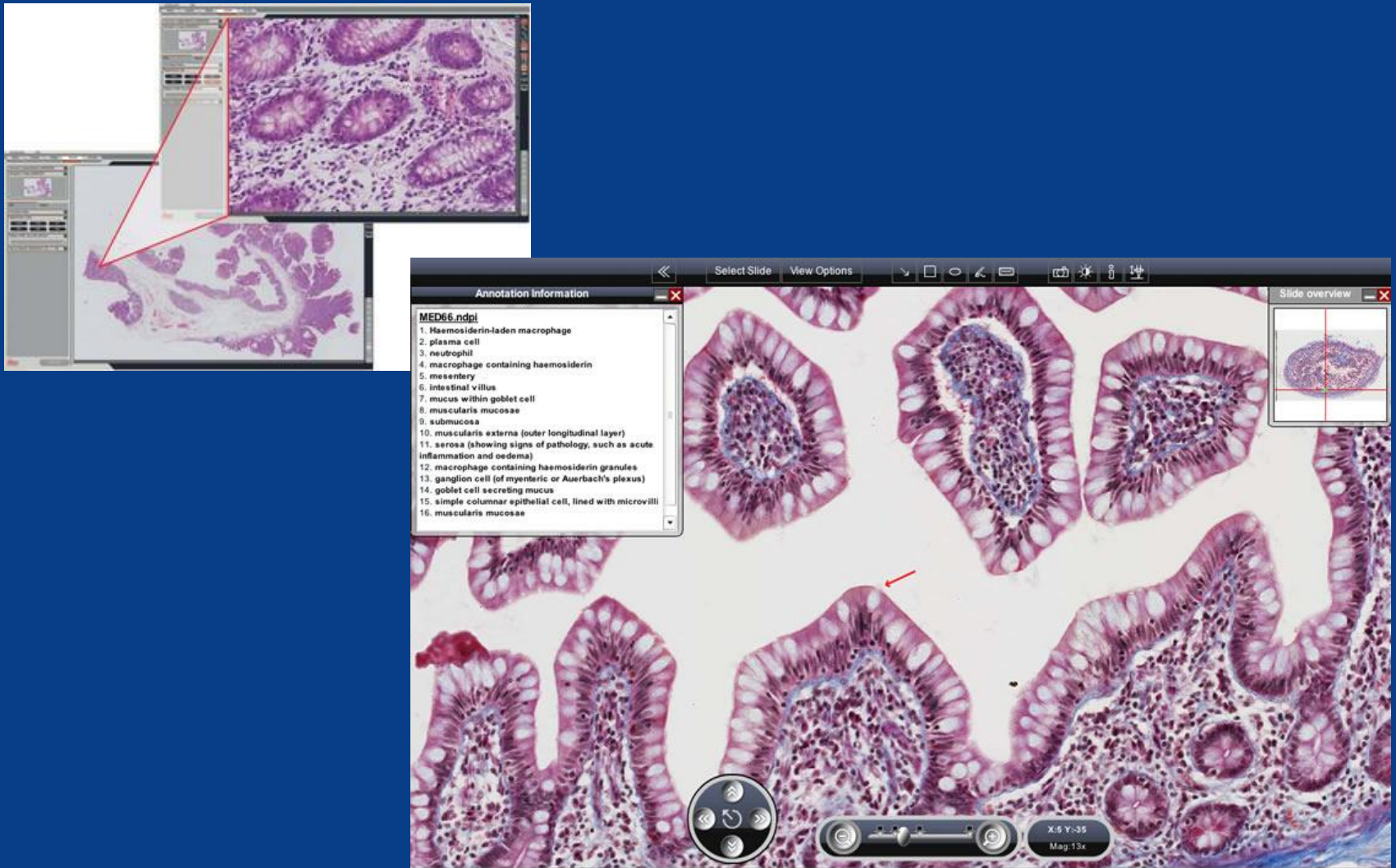
CUHK campus



PWH campus



it might look like this ...



and, perhaps, like this

The screenshot displays the SlidePath software interface. The main window shows a histological slide with several red annotations (circles and rectangles) highlighting specific areas. On the left, the 'Annotation Information' panel is open, displaying a list of questions and their corresponding answers. On the right, the 'Slide Overview' panel shows a small thumbnail of the entire slide. In the foreground, the 'Questionnaire Manager' dialog box is open, allowing the user to add or modify questions. The dialog box contains fields for the question text, answer type, and a list of possible answers. It also includes options for whether the question is compulsory and whether it should be linked to specific views or multimedia.

Annotation Information

Narrative | **Annotations**

At low power:
Is the area normal or abnormal?
Abnormal. The normal arrangement of mucosa, submucosa, muscularis propria and serosa/mesorectum is visible at the **edges** of the specimen but is disturbed by a **lesion** in the center of the section.
At this magnification the lesion appears **deeper** blue/purple than the adjacent **normal** tissue. This may be due to increased cellularity, increased nuclear-cytoplasmic ratio or nuclear hyperchromatism.

Describe the abnormality:
Is it localised or diffuse?
It is localised.

If localised, where is it centered?
At this magnification it appears centered on the mucosa and appears to protrude into the lumen.

If localised, is it well circumscribed?
It does not appear well circumscribed or encapsulated.

At higher magnification:
Is the abnormal area comprised of a dominant cell type or a mixture of cells?
There is a dominant cell type.

If there is a dominant cell type is it epithelial (with cells tending to cohesion with the formation of groups, sheets, islands, possibly with specific architectural features: tubules, glands, papillae)(cytoplasm tends to be more abundant and may -on higher power show evidence of keratinisation or intracytoplasmic secretions)?
Yes.

If the dominant abnormal cell population is epithelial, is the architecture normal or abnormal?
The architecture of the glands is abnormally **complex and branched** (compare with the **simple parallel glands** of the normal epithelium).

Are abnormal epithelial groups seen in areas where they are not normally found?
Yes. The abnormal glands extend through the **muscularis mucosae** into but not through the **muscularis propria**.

Questionnaire Manager
Add or Modify Question

* Question Text
Please provide your overall assessment of this case

* Answer type:
Multiple choice
☒ Allow single selection
☐ Allow multiple selections

* Please enter choices

Invasive	Add
Normal	Delete
Benign	Delete
Atypical	Delete
In situ / Microinvasive	Delete

Is this question compulsory?
☒ Yes
☐ No

* Do you want to link this question to specific views or multimedia?
None
- Please choose -
None
Link to field of view
Link question to an annotation
Link question to a file

try these yourselves ...

DSB Login

<http://eu-demo-dih.slidepath.com/dsb>

username: dyoung

password: dyoung

DIH Login (TissueIA, OpTMA)

<http://eu-demo-dih.slidepath.com/dih>

username: dyoung

password: dyoung